

Malignant anomalous right coronary artery detected by multidetector row computed tomography coronary angiography

Bhawna Satija, Kumar Sanyal, Kumar Katyayni

Department of Radiodiagnosis and Imaging, Employees' State Insurance Corporation Model Hospital and Post Graduate Institute of Medical Sciences and Research, Basai Darapur, New Delhi, India

Address for correspondence: Dr. Bhawna Satija, Department of Radiodiagnosis and Imaging, B-1/57, First Floor, Paschim Vihar, New Delhi – 110 063, India. E-mail: satijabhawna@yahoo.com

ABSTRACT

We report a case of an anomalous origin of a right coronary artery from the left coronary sinus with an inter-arterial course, between the aorta and the main pulmonary artery. This variant has been called malignant because of its association with sudden death, especially in young asymptomatic athletes. Although these variants are rare, knowledge of cross sectional anatomy of the coronary arteries and their variants is critical, especially because some variants are associated with sudden death.

Key words: Inter arterial, multidetector row computed tomography coronary angiography, right coronary artery

INTRODUCTION

Congenital anomalies of the coronary arteries, though uncommon, are an important cause of chest pain and in some cases can produce hemodynamically significant abnormalities, and even sudden cardiac death. Malignant anomalous right coronary, with an incidence of 0.03-0.17% of patients undergoing angiography, is a rare form of such congenital anomalies. The development of electrocardiography (ECG) gated multidetector row computed tomography (MDCT) allows accurate and noninvasive detection of coronary artery anomalies. Knowledge of normal CT appearances of various anomalies and an understanding of their clinical significance is essential for correct diagnosis.

CASE REPORT

A 38 year old male presented with complaints of chest pain,

aggravated by physical stress, of more than four months duration. There were no risk factors or any significant past medical history. His routine blood examination, chest radiograph and electrocardiography (ECG) were unremarkable. The exercise treadmill test showed ST depression in lead VI. The patient was referred to the radiology department to undergo CT coronary angiography. CT coronary angiography was performed using a 64 slice CT scanner (Brilliance-64, Philips, The Netherlands). The total calcium score was zero. The following parameters were used: 120 KVp, 800 mAs, rotation time: 0.4 s, pitch: 0.2 mm and collimation: 64 × 0.625mm. Using a dual head pressure injector (Mallinckrodt), 80 ml of nonionic iodinated contrast (Iopamiro 370, Bayer, Germany) was administered at the rate of 5 ml/sec, followed by 20 ml of saline. The total scan time was 8.6 seconds. Reconstruction was done with 0.6 mm slice thickness at 0.5 mm increment. CT Coronary angiography showed the right coronary artery originating from the left coronary sinus, coursing between the aortic root and pulmonary artery with a narrowed proximal segment. [Figures 1 and 2]. The rest of the coronary arteries, including the left main LCA, the left anterior descending and the left circumflex were normal in course.

DISCUSSION

Anomalies of coronary arteries may be found incidentally

Access this article online	
Quick Response Code: 	Website: www.jcdronline.com
	DOI: 10.4103/0975-3583.91598

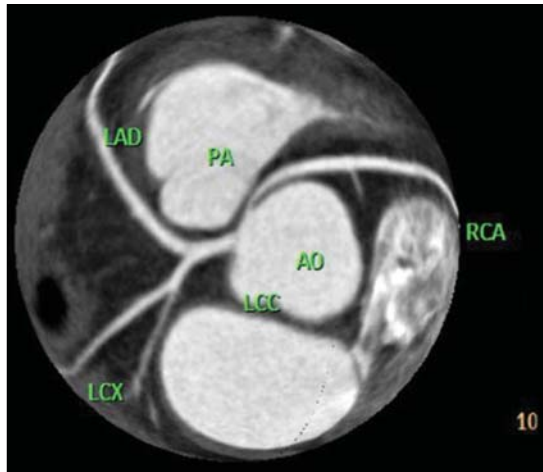


Figure 1: Maximum intensity projection of top of heart showing both right coronary artery (RCA) and left coronary artery (LCA) originating from left coronary sinus. RCA has a slit-like ostium and courses between pulmonary artery (PA) and aorta (A)

in 0.3-1% of healthy individuals.^[1] The coronary artery anomalies can be classified into anomalies of origin, course or termination or as hemodynamically significant or insignificant.^[2] Hemodynamically significant anomalies are characterized by abnormalities of myocardial perfusion, leading to increased risk of myocardial ischemia or sudden death.^[3] These include an anomalous origin of either the LCA or RCA from the pulmonary artery, an anomalous course between the pulmonary artery and aorta (inter-arterial) of either the RCA arising from the left sinus of Valsalva or the LCA arising from the right sinus of Valsalva, and, occasionally myocardial bridging or congenital coronary artery fistula.

The RCA arising from the left sinus of Valsalva as a separate vessel or as a branch of a single coronary artery has an incidence of 0.03-0.17% of patients undergoing angiography.^[4,5] The anomalous origin may have inter-arterial, retro-aortic, prepulmonic or septal (subpulmonic) course, the most common being inter-arterial. The incidence of sudden death with this anomaly is estimated at 25-40% and is associated with exercise in half of the reported cases.^[6] Various theories have been proposed for this association, including slit like ostium, acute angulation at the origin and compression of the vessel between the aorta and pulmonary artery.

The choice of treatment for this congenital anomaly is still controversial; however, because of significant hemodynamic consequences and propensity to cause sudden death, most of the literature advocates definite surgical revascularization in all cases, and the different options available include coronary artery bypass grafting, reimplantation of the coronary ostia and unroofing of

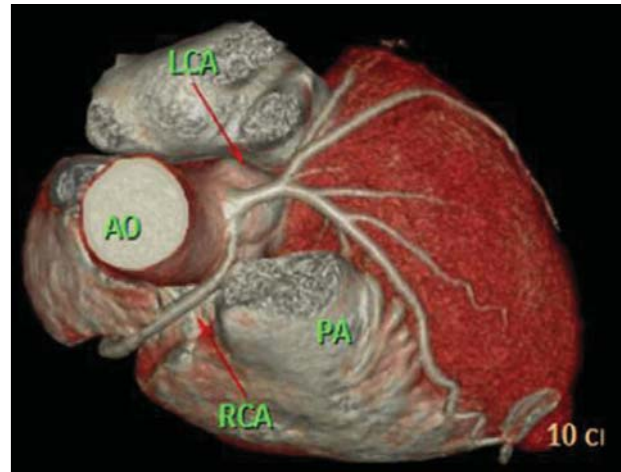


Figure 2: Volume rendered image of same showing anomalous, interarterial course of right coronary artery (RCA), between pulmonary artery (PA) and aorta (A)

the coronary artery, the last being considered the best solution if anatomically feasible.^[7] In Japan, the treatment for this condition is conservative with the patient being treated medically with beta blockers.^[8] CT coronary angiography was made possible with the introduction of MDCT and development of ECG gated scanning. For several decades, the imaging of coronary arteries was done with conventional angiography. However, it has been reported that anomalies of coronary arteries detected on conventional angiography were only 35% of those detected on 16 slice MDCT.^[9] Although coronary artery anomalies are far less common than acquired coronary artery disease, their propensity to cause premature cardiac morbidity and mortality especially in young adults make them significant. In a study by Eikart *et al.*, cardiac abnormality was responsible for 51% of sudden deaths in young adults, with coronary artery abnormality being the most common cardiac abnormality (61%).^[10]

In conclusion, we describe a 38 year old man with an anomalous right coronary artery, arising from the left sinus of Valsalva and coursing between the aortic root and pulmonary artery. This case report emphasizes the role of non-invasive ECG gated MDCT coronary angiography in accurate detection of coronary artery anomalies.

REFERENCES

1. Angelini P, Velasco JA, Flamm S. Coronary anomalies: Incidence, pathophysiology and clinical relevance. *Circulation* 2002;105:2449-54.
2. Kim SY, Seo JB, Do KH, Heo JN, Lee JS, Song JW, *et al.* Coronary artery anomalies: Classification and ECG-gated multi-detector row CT findings with angiographic correlation. *Radiographics* 2006;26:317-33.
3. Reagan K, Boxt LM, Katz J. Introduction to coronary arteriography. *Radiol*

- Clin North Am 1994;32:419-33.
4. Yamanaka O, Hobbs RE. Coronary artery anomalies in 126,595 patients undergoing coronary angiography. Cathet Cardiovasc Diagn 1990;21: 28-40.
 5. Kimbiris D, Iskandrian AS, Segal BL, Bemis CE. Anomalous aortic origin of coronary arteries. Circulation 1978;58:606-15.
 6. Frescura C, Basso C, Thiene G. Anomalous origin of coronary arteries and risk of sudden death: A study based on the autopsy population of congenital heart disease. Hum Pathol 1998;29:689-95.
 7. Fedoruk LM, Kern JA, Peeler BB, Kron IL. Anomalous origin of the right coronary artery: Right internal thoracic artery to right coronary artery bypass is not the answer. J Thorac Cardiovasc Surg 2007;133:456-60.
 8. Ho JS, Strickman NE. Anomalous origin of the right coronary artery from the left coronary sinus. Tex Heart Inst J 2002;29:37-9.
 9. Shi H, Aschoff AJ, Brambs HJ, Hoffmann MH. Multislice CT imaging of anomalous coronary arteries. Eur Radiol 2004;14:2172-81.
 10. Eckart RE, Scoville SL, Campbell CL. Sudden death in young adults: A 25-year review of autopsies in military recruits. Ann Intern Med 2004;141:829-34.

How to cite this article: Satija B, Sanyal K, Katyayni K. Malignant anomalous right coronary artery detected by multidetector row computed tomography coronary angiography. J Cardiovasc Dis Res 2012;3:40-2.

Source of Support: Nil, **Conflict of Interest:** None declared.